

Case of Ovarian Hyperstimulation Syndrome with Ovarian Torsion: An Unusual Complication of Primary Untreated Hypothyroidism

GWENDOLYN FERNANDES¹, MANALI PATIL², CAROLINE THOMSON³

ABSTRACT

Ovarian Hyperstimulation Syndrome (OHSS) is an extremely unusual complication of ovarian induction therapy given for infertility. OHSS can also occur spontaneously in ovulation cycles linked to polycystic ovarian disease, multiple gestations, molar pregnancy, pituitary adenomas and very rarely, hypothyroidism. It can result in significant morbidity and mortality in severe forms due to thrombosis and organ failure. A 28-year-old non pregnant woman presented to the emergency services with severe abdominal pain associated with nausea, vomiting, constipation and burning micturition. The symptoms began four to five days ago and the pain, which was initially localised to the left iliac fossa, progressed to involve the entire abdomen. Ultrasonography revealed large, bulky, oedematous ovaries with multiple cysts of varying sizes, indicative of OHSS, along with torsion of the left ovary. There was no history of receiving beta-human Chorionic Gonadotropin (β -hCG), clomiphene citrate, estradiol, oral contraceptive pills, or any other ovulation induction therapy. A salpingo oophorectomy was done for the left ovary and cystectomy with ovarian reconstruction was done for the right ovary. Histopathological examination confirmed OHSS (Type 3) with ovarian torsion. The patient had a diagnosis of primary hypothyroidism during pregnancy which was three and half years ago and was treated with Thyroxine 75 μ g per day. However, stopped thyroxine on her own immediately after delivery. Thyroid Stimulating Hormone (TSH) levels was 110 μ g, T3 was 16 ng/mL and T4 was 0.91 μ g/dL. Thyroxine 100 μ g/day was started and the contralateral ovary returned to the normal size on ultrasonography within a period of three months. Thus, OHSS resulted from primary hypothyroidism and was cured with thyroid hormone replacement. OHSS may also be considered in the differential diagnosis in patients of hypothyroidism patients presenting with abdominal symptoms.

Keywords: Ascites, Ovarian cyst, Ovary, Ovulation induction therapy, Thyroid

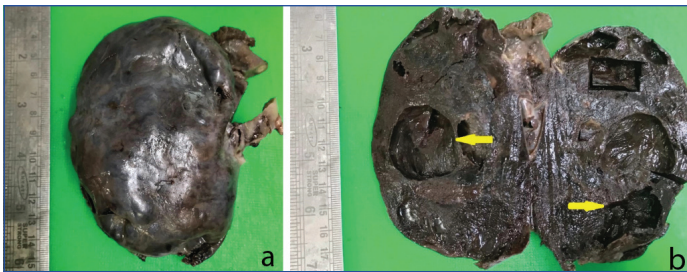
CASE REPORT

A 28-year-old non pregnant woman, para 1 living 1 with a three-year-old child, presented to the emergency services with severe abdominal pain, nausea, vomiting, constipation and burning micturition for four to five days. The pain was initially localised to the left iliac fossa but later involved the entire abdomen. Her last menstrual period was two days before admission. There was no history of taking medication for ovulation induction or drugs like β -hCG, clomiphene citrate, prolactin, prostaglandins, oestrogens, oral contraceptive pills, or any other medications. The patient had a history of hypothyroidism diagnosed 3.5 years ago during pregnancy, for which she was treated with 75 μ g Tab. Thyroxine. The patient, however, took thyroxine during pregnancy but stopped it on her own in the immediate postdelivery period. No monitoring of thyroid hormone levels was done. The patient also had a history of oligomenorrhoea with menstrual cycles occurring after 35-40 days since puberty.

On general examination, vitals were stable with a pulse rate of 86 beats per minute, blood pressure of 104/80 mmHg, SpO₂ of 98% and weight of 56 kg. The patient had mild pallor but no icterus, oedema, clubbing, or cyanosis. No goitre was seen. The abdomen was mildly distended and tender. Rest of the systemic examination was normal. The haematological and biochemical examinations were normal except for mild anaemia with haemoglobin levels of 9.8 g/dL (reference range: 12-16 g/dL). Thyroid profile showed T3 of 16 ng/dL (reference range: 60-180 ng/dL), T4 levels of 0.91 μ g/dL (reference range: 5-12 μ g/dL), TSH of 110 IU/L (reference range: 0.4-4 IU/mL) and Thyroid Peroxidase antibody levels (TPO) of 533 IU/mL (reference range: <30 IU/mL). The coagulation profile was normal.

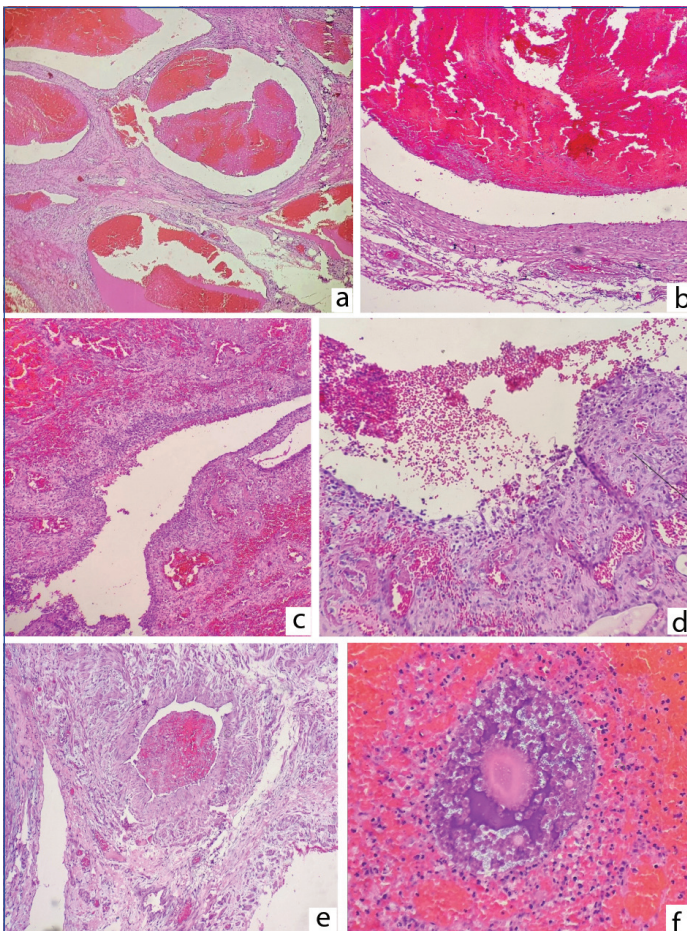
Ultrasonography of abdomen and pelvis was done, which showed an anteverted uterus with an endometrial thickness of 2.8 cm. The right ovary was 9.6×7.7×4.2 cm with a volume of 164 cc and the left ovary measured 8.2×7×7 cm with a volume of 212 cc. Both ovaries were large, bulky, oedematous with multiple simple cysts of varying sizes. The largest cyst in the right ovary measured 4.7×3.4 cm and in the left ovary measured 4.1×3 cm. The intervening ovarian parenchyma did not show any arterial or venous vascularity except at the periphery. The left ovary also showed features of torsion. Free fluid was seen in the pelvis. The diagnosis on ultrasonography was OHSS with torsion of the left ovary. The patient underwent an emergency exploratory laparotomy with left salpingo-oophorectomy and right ovarian cystectomy with ovarian reconstruction. Intraoperatively, the left ovary was large, haemorrhagic, oedematous and showed torsion with two rotations of the pedicle. The right ovary was also enlarged with multiple, simple ovarian cysts. The specimen of left salpingo-oophorectomy and right ovarian cystectomy was sent for histopathological examination. On gross examination, the left ovarian mass measured 12×10×5 cm and was accompanied by an oedematous left fallopian tube [Table/Fig-1a]. The cut surface of the left ovary was dark brown, congested, cyanotic and showed multiple cysts varying in size from 0.8-4 cm [Table/Fig-1b]. The right ovarian cyst wall was received as a flat bit of tissue which was reddish-brown and markedly congested.

On microscopy, the left ovary showed extensive areas of haemorrhage, oedema, angiogenesis and areas of infarction (coagulative necrosis). Multiple cysts of varying sizes were seen, with some showing fibrinous material within their lumen [Table/Fig-2a,b]. Most of the cysts did not have any lining epithelium, but



[Table/Fig-1]: (a) Left salpingo-oophorectomy specimen showing a dusky, cyanotic, markedly enlarged left ovary following torsion. Fallopian tube is seen in the right upper corner; (b) Cut surface of the left ovary shows a haemorrhagic, oedematous parenchyma with multiple cysts of varying sizes. Arrows point to the cysts.

few of them showed a lining of follicular epithelium [Table/Fig-2c,d]. Fibrin thrombi were seen in many of the ovarian parenchymal blood vessels [Table/Fig-2e]. Preserved ovarian stroma with Graafian follicles was also seen in the wall of the cyst [Table/Fig-2f]. The attached fallopian tube showed normal histology. The right ovarian cyst showed a cyst wall lined by similar follicular cells. A diagnosis of OHSS, type 3 with massive enlargement of the ovaries and torsion of the left ovary, probably resulting from hypothyroidism was made.



[Table/Fig-2]: (a) Left ovary showing multiple blood-filled cysts amidst an oedematous stroma (H&E,40x); (b) Another cyst without any epithelial lining. Haemorrhagic contents are seen within the cyst (H&E,400x); (c) Cyst lined by follicular epithelium with haemorrhages in the ovarian stroma (H&E,100x); (d) Higher magnification shows a cyst wall lined by follicular epithelium (H&E,400x); (e) Intraparenchymal blood vessels showing fibrin thrombi (H&E,100x); (f) Graafian follicle seen within areas of haemorrhages (H&E,400x).

The patient was immediately started on **thyroxine** 100 µg per day. Ultrasonography done after three months showed a normal-sized right ovary.

DISCUSSION

The OHSS is a serious complication of ovulation induction therapy used for infertility and assisted reproduction, with a potential for grave morbidity and mortality [1]. It is usually seen following ovulation induction therapy and drugs like β -hCG, clomiphene

citrate, oestrogen and oral contraceptive pills [1]. The incidence of moderate OHSS is 3-6%, while the incidence of severe OHSS is 0.2-1%, as per World Health Organisation (WHO) and other studies [2,3]. OHSS is characterised by bilateral, symmetric enlargement of the ovaries with oedema and cysts of varying sizes, due to increased vascular permeability and shift of fluid from the intravascular to extravascular space [1]. The aetiopathogenesis of OHSS is not well understood and it can arise in a background of various settings like ovulation induction medication, pituitary adenoma and hypothyroidism [4-6].

In case of hypothyroidism, the aetiopathogenesis is possibly based on the preferential formation of estriol via the 16-hydroxylation pathway instead of the normal 2-hydroxylation, which has been demonstrated in hypothyroid patients. Excessive gonadotropin release, due to decreased feedback regulation caused by the substitution of estradiol by the less potent estriol, would result in excessive ovarian stimulation [7]. Ovarian Hyperstimulation Syndrome (OHSS) results from fluid shifts from the intravascular compartment to the interstitial space because of increased capillary permeability resulting from the production of Vascular Endothelial Growth Factor (VEGF), which causes neoangiogenesis [8]. This can lead to haemoconcentration, electrolyte imbalance, hypoalbuminemia, oliguria and effusions that can result in life-threatening complications like thrombosis, respiratory failure, hepatic failure and renal failure [4,8].

Mild OHSS is characterised by abdominal distention and discomfort, nausea, vomiting, diarrhoea, with an ovarian enlargement from 5-12 cm [4,9]. Moderate OHSS is characterised by above mentioned features of OHSS plus ultrasonographic evidence of ascites [4,9]. Severe OHSS is characterised by massive ovarian enlargement, ascites, pleural effusion, peritonitis, hypercoagulable state, dyspnoea, acute renal failure, hypotension, abdominal pain and hypovolemia [4,9]. Risk factors for OHSS include young age, low body mass index, polycystic ovarian syndrome and history of OHSS. OHSS has classical radiological features and radiographs show enlarged, bulky, oedematous ovaries with multiple cysts and ascites and the ultrasonography is quite diagnostic [10]. The enlarged ovaries can undergo torsion or rupture due to the large oedematous ovarian structure. In the present case, a salpingo-oophorectomy was done for the torsion of the left ovary.

OHSS is classified by De Leener A et al., into three types based on clinical presentation and Follicle Stimulating Hormone (FSH) receptor mutation [11]. Type 1 corresponds to mutated FSH receptor cases with abdominal pain and discomfort. Type 2 corresponds to a high level of β -HCG and type 3 is associated with hypothyroidism. The current case corresponds to type 3, moderate OHSS. Mild to moderate OHSS is a self-limiting disease and treatment is conservative and symptomatic. Severe OHSS may require intense medical treatment, replacement of body fluids and surgery in case of ovarian torsion or rupture. The present case required a salpingo-oophorectomy for torsion of the ovary. Hypothyroidism requires replacement therapy with thyroid hormone.

In a recent comprehensive review of literature review (1980-2024) published in May 2024 by Zhou J et al., 36 cases of OHSS combined with hypothyroidism were collected and studied. These included pregnant, non pregnant, as well as iatrogenic OHSS with embryo transfer. Ovarian torsion was reported in a couple of cases of these cases. They emphasise ultrasound examination and measurement of TSH levels for diagnosis of this disease [5]. Apart from these 36 cases, few more recent cases of OHSS associated with hypothyroidism were found [12-14]. Some authors recommend evaluation for hypothyroidism in all patients with spontaneous OHSS [15]. Present case was similar to all the cases of OHSS resulting from primary hypothyroidism in non pregnant patients. Awareness of hypothyroidism as possible cause of OHSS makes the diagnosis difficult to miss.

CONCLUSION(S)

Hypothyroidism is a very common medical condition and untreated hypothyroidism with high TSH levels has the potential to cause OHSS. OHSS, though rare, may be considered in the differential diagnosis of patients with untreated hypothyroid patients with abdominal symptoms. OHSS is highly amenable to medical treatment and ovaries return to normal size within a few months following treatment with thyroxine. Ovarian torsion and rupture require oophorectomy.

REFERENCES

- [1] Whelan JG 3rd, Vlahos NF. The ovarian hyperstimulation syndrome. *Fertil Steril*. 2000;73(5):883-96. Doi: 10.1016/s0015-0282(00)00491-x. PMID: 10785212.
- [2] Binder H, Dittrich R, Einhaus F, Krieg J, Müller A, Strauss R, et al. Update on ovarian hyperstimulation syndrome: Part 1--Incidence and pathogenesis. *Int J Fertil Womens Med*. 2007;52(1):11-26. PMID: 17987884.
- [3] Delvigne A, Rozenberg S. Epidemiology and prevention of ovarian hyperstimulation syndrome (OHSS): A review. *Hum Reprod Update*. 2002;8(6):559-77. Doi: 10.1093/humupd/8.6.559. PMID: 12498425.
- [4] Kumar P, Sait SF, Sharma A, Kumar M. Ovarian hyperstimulation syndrome. *J Hum Reprod Sci*. 2011;4(2):70-75. Doi: 10.4103/0974-1208.86080. PMID: 22065820; PMCID: PMC3205536.
- [5] Zhou J, Chen Y, Bai L, Zhou W, Yang H, Chen Y, et al. Ovarian hyperstimulation syndrome combined with hypothyroidism: A comprehensive review. *J Ovarian Res*. 2024;17(1):98. Doi: 10.1186/s13048-024-01406-3. PMID: 38725001; PMCID: PMC11084021.
- [6] Guerra M, Marado D, Silva F, Almeida MC. Severe primary hypothyroidism and ovarian hyperstimulation syndrome in a spontaneous pregnancy: A case report. *AME Case Rep*. 2024;8:26.
- [7] Scommegna A. Spontaneous ovarian hyperstimulation syndrome associated with hypothyroidism. *Am J Obstet Gynecol*. 1989;160(5 Pt 1):1220-22. Doi: 10.1016/0002-9378(89)90196-8. PMID: 2729396.
- [8] Elchalal U, Schenker JG. The pathophysiology of ovarian hyperstimulation syndrome--views and ideas. *Human Reproduction*. 1997;12(6):1129-37. <https://doi.org/10.1093/humrep/12.6.1129>.
- [9] Golan A, Ron-el R, Herman A, Soffer Y, Weinraub Z, Caspi E. Ovarian hyperstimulation syndrome: An update review. *Obstet Gynecol Surv*. 1989;44(6):430-40. Doi: 10.1097/00006254-198906000-00004. PMID: 2660037.
- [10] Smith LP. Ultrasound and ovarian hyperstimulation syndrome. In: Stadtmauer L, Tur-Kaspa I. (eds) *Ultrasound imaging in reproductive medicine*. Springer, Cham. 2019. https://doi.org/10.1007/978-3-030-16699-1_19.
- [11] De Leener A, Montanelli L, Van Durme J, Chae H, Smits G, Vassart G, et al. Presence and absence of follicle-stimulating hormone receptor mutations provide some insights into spontaneous ovarian hyperstimulation syndrome physiopathology. *J Clin Endocrinol Metab*. 2006;91:555-62.
- [12] Prabha K, Jebasingh KF, Londhe V, Thomas N. The clinical diversity of primary hypothyroidism presenting as a spontaneous ovarian hyperstimulation syndrome. *Endocrinol Diabetes Metab Case Rep*. 2024;2024(3):23-0084. Doi: 10.1530/EDM-23-0084. PMID: 39342970; PMCID: PMC11466253.
- [13] Alzebedi J A, Almushri K, Elmoheen R. Spontaneous ovarian hyperstimulation syndrome associated with primary hypothyroidism. *Cureus*. 2023;15(1):e33247. Doi:10.7759/cureus.33247.
- [14] Annamalai AK, Hemamalini R, Gurnell M. Bilateral enlarged ovarian masses and hypothyroidism. *Eur J Intern Med*. 2023;112:113-14.
- [15] Pail SM, Bagri N, Ghas RG. Hypothyroidism induced spontaneous ovarian hyperstimulation syndrome: A rare yet interesting dilemma. *The New Indian J Obstet Gynecol*. 2023;10(1):229-32.

PARTICULARS OF CONTRIBUTORS:

1. Professor (Additional), Department of Pathology, G. S. Medical College and K.E.M. Hospital, Mumbai, Maharashtra, India.
2. Fellow, Department of Pathology, G. S. Medical College and K.E.M. Hospital, Mumbai, Maharashtra, India.
3. Ex-Resident, Department of Pathology, G. S. Medical College and K.E.M. Hospital, Mumbai, Maharashtra, India.

NAME, ADDRESS, E-MAIL ID OF THE CORRESPONDING AUTHOR:

Dr. Gwendolyn Fernandes,
B2-801, Mahindra Vivante Suren Road, Off Western Express Metro Station,
Andheri (East), Mumbai-400093, Maharashtra, India.
E-mail: drgwenfern@yahoo.co.in

PLAGIARISM CHECKING METHODS: [Jain H et al.]

- Plagiarism X-checker: Apr 11, 2024
- Manual Googling: Oct 31, 2024
- iThenticate Software: Nov 02, 2024 (15%)

ETYMOLOGY: Author Origin

EMENDATIONS: 5

AUTHOR DECLARATION:

- Financial or Other Competing Interests: None
- Was informed consent obtained from the subjects involved in the study? Yes
- For any images presented appropriate consent has been obtained from the subjects. Yes

Date of Submission: **Apr 10, 2024**
Date of Peer Review: **Apr 27, 2024**
Date of Acceptance: **Nov 05, 2024**
Date of Publishing: **Dec 01, 2024**